

## CASE NOTE

# Control of the bleeding gallbladder bed using a pedicled falciform ligament flap based on the left inferior phrenic artery and middle segment hepatic artery

Vijay Naraynsingh, MBBS\*  
Michael J. Ramdass, MBBS†

From the Departments of Surgery,  
\*University of the West Indies and the  
†General Hospital, Port-of-Spain,  
Trinidad, West Indies

**Correspondence to:**  
Dr. M.J. Ramdass  
Department of Surgery  
General Hospital  
Port-of-Spain  
Trinidad, West Indies  
fax 868 663-9064  
jimmyramdass@gmail.com

## CASE REPORT

A 45-year old woman presented with a 3-day history of right upper quadrant pain, which suddenly became generalized. On examination, the patient was septic, tachycardic and tachypnoeic with a distended, tender abdomen. There were no surgical scars, and hernial orifices were normal. Abdominal radiographs showed dilated small bowel with leukocytosis on full blood count. We found a perforated gallbladder with acute cholecystitis and bilious peritonitis at laparotomy.

After peritoneal toilet, we performed a standard cholecystectomy. However, there was a severe pericholecystic reaction, which left a briskly bleeding gallbladder bed. Twice, we packed the area with a large abdominal swab; however, on removal on both occasions, brisk bleeding recurred owing to the clot being pulled off along with the abdominal pack. No modern hemostatic agents such as gelfoam or surgicel were available at the time.

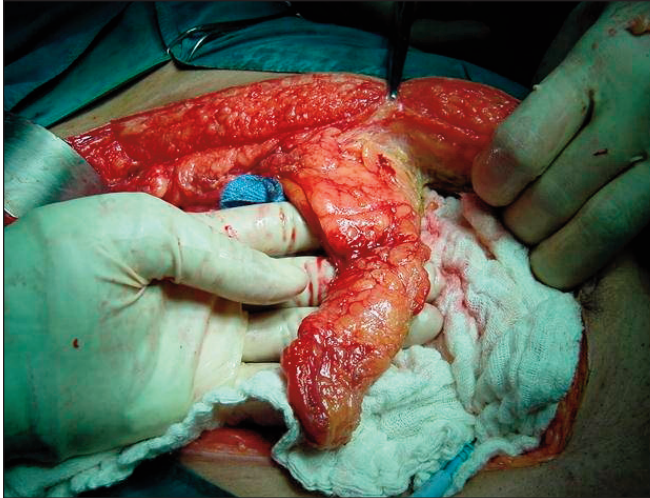
We mobilized the falciform ligament on its pedicle, maintaining the vascular supply from the left inferior phrenic artery and middle segment hepatic artery (Fig. 1). We then applied it to the gallbladder bed and compressed the area with large abdominal packs, which we gently removed after about 10 minutes with extra caution not to disturb the flap (Fig. 2). This achieved hemostasis, and the patient recovered uneventfully.

## DISCUSSION

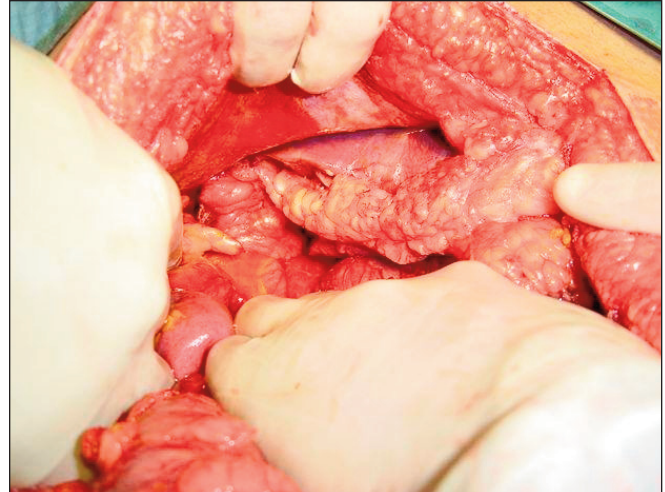Although most gallbladder surgery is now performed laparoscopically, there are scenarios when open surgery is necessary such as perforation, empyema, gangrene, previous major surgery with adhesions or carcinoma.

In cases when the gallbladder has been inflamed for more than 72 hours, a severe pericholecystic reaction occurs, making surgery potentially hazardous.<sup>1</sup> The inflamed gallbladder wall and surrounding hepatic connective tissue involved in the inflammatory process become fused together, thus preventing dissection in the plane. As a result, the gallbladder affected by acute cholecystitis frequently has to be dissected directly out of the liver parenchyma.<sup>2</sup> The resulting diffuse bleeding can be difficult to control by cauterization, with the added danger of postoperative bile leakage.<sup>2</sup> Today, the use of fibrin sealing is accepted practice in the treatment of oozing hemorrhage from the surface of the liver following resective surgery and for the prevention of postoperative biliary fistulae.<sup>2,3</sup> In these difficult cases, subtotal cholecystectomy has been documented to minimize morbidity and avoid bleeding and difficult dissection in the Calot triangle.<sup>4</sup>

Occasionally, surgeons are still faced with a bleeding gallbladder bed in the



**Fig. 1.** A perioperative photograph showing the pedicled falciform ligament flap mobilized on the left inferior phrenic artery and middle segment hepatic artery.



**Fig. 2.** A perioperative photograph showing hemostasis achieved by application of a pedicled falciform ligament flap to the raw hepatic surface and compressed for 10 minutes.

absence of modern hemostatic agents such as surgical, gelfoam or fibrin glue.<sup>3</sup>

Various autologous flaps of the omentum, rectus muscle and falciform ligament have also been described. These include repair of common bile duct injury with the round and falciform ligament after clip necrosis, plastic repair of partial lesions of the principal bile duct by a pedicled flap of the falciform ligament of the liver, falciform ligament for the residual cavity of liver hydatidosis, hemostasis of a ruptured liver tumour using gallbladder serosa and falciform ligament, and hemostasis of the gallbladder bed by using a muscle flap. Despite this diversity of experience, a search of the literature revealed that the use of the falciform ligament flap in the bleeding gallbladder bed has not been clearly described in this particular scenario.

The flap is based on the blood supply to the falciform ligament, which was described in 2004 by Li and colleagues.<sup>5</sup> Their study identified the clinical significance of the morphology and blood supply of the falciform ligament in laparoscopic surgery. They observed the structure, blood vessel distribution and anastomoses of the falciform ligament in 20 cases of living laparoscopy, 30 cadaveric specimens injected with latex and 5 cadaveric specimens with Indian ink and hyaline. They reported that the left inferior phrenic artery and middle segment artery of the liver formed a vessel that arched and gave off 6–12 branches to the falciform ligament. The veins of the falciform ligament drained into the left inferior phrenic vein and were not accompanied by any artery. The authors concluded that the vessels of the falciform ligament anastomose with multiple vessels and form an important pathway

of the collateral circulation in the liver.<sup>5</sup>

In clinical practice, the falciform ligament should be mobilized on a pedicled flap originating from the left inferior phrenic and middle segment hepatic vessels and then applied to the bleeding gallbladder bed. Compression with 2 large abdominal packs should be done for about 10 minutes, followed by gentle removal of the packs so as not to disturb the pedicled falciform ligament flap.

We hope that the anatomic and clinical significance of the pedicled falciform ligament flap can be used by other surgeons facing similarly difficult patient scenarios.

**Competing interests:** None declared.

## References

1. Duca S, Bala O, al-Hajjar N, et al. [Laparoscopic cholecystectomy: incidents and complications. Analysis of 8002 consecutive cholecystectomies performed at the Surgical Clinic III Cluj-Napoca] [Article in Romanian]. *Chirurgia (Bucur)* 2000;95:523-30.
2. Köckerling F, Schneider C, Reymond MA, et al. [Controlling complications in laparoscopic cholecystectomy: diffuse parenchyma haemorrhage in the liver parenchyma] [Article in German]. *Zentralbl Chir* 1997;122:405-8.
3. Browder IW, Litwin MS. Use of absorbable collagen for hemostasis in general surgical patients. *Am Surg* 1986;52:492-4.
4. Bornman PC, Terblanche J. Subtotal cholecystectomy: for the difficult gallbladder in portal hypertension and cholecystitis. *Surgery* 1985;98:1-6.
5. Li XP, Xu DC, Tan HY, et al. Anatomical study on the morphology and blood supply of the falciform ligament and its clinical significance. *Surg Radiol Anat* 2004;26:106-9.

Copyright of *Canadian Journal of Surgery* is the property of *Canadian Medical Association* and its content may not be copied or emailed to multiple sites or posted to a listserv without the copyright holder's express written permission. However, users may print, download, or email articles for individual use.