

## ◆ CASO CLÍNICO

# Cecal volvulus and mucocele of the appendix

Vijay Naraynsingh, Seetharaman Hariharan, Ian Sammy

*Department of Clinical Surgical Sciences. The University of the West Indies, St. Augustine. Trinidad, West Indies.*

*Acta Gastroenterol Latinoam 2010;40:354-356*

### Summary

*We report the case of a 75-year-old woman who presented the association of a cecal volvulus with an appendiceal mucocele. A laparotomy showed these two findings and a right hemicolectomy with an end-to-end ileo-transverse colonic anastomosis was done. The role of plain radiograph and computerized tomographic imaging in the diagnosis of this entity is discussed. To our knowledge, this association has not been reported in the literature.*

**Key words.** *Cecal volvulus, appendiceal mucocele.*

### Vólvulo cecal y mucocele del apéndice

#### Resumen

*Comunicamos el caso de una mujer de 75 años de edad que presentó la asociación de un vólvulo cecal con un mucocele apendicular. Una laparotomía mostró estos dos hallazgos y se realizó una hemicolectomía derecha con una anastomosis colónica ileo-transversa término-terminal. Se discute el papel de la radiografía simple y la tomografía computada en el diagnóstico de esta entidad. En nuestro conocimiento, esta asociación no se ha reportado en la literatura.*

**Palabras claves.** *Vólvulo cecal, mucocele apendicular.*

Volvulus of the caecum is a well recognized but uncommon entity. It is usually associated with abnormal laxity of the right mesocolon and most commonly presents in the 20- to 35-year-old age group.<sup>1</sup>

**Correspondence:** Seetharaman Hariharan  
Senior Lecturer. Department of Clinical Surgical Sciences. Faculty of Medical Sciences. The University of the West Indies. Eric Williams Medical Sciences Complex. Mount Hope. Trinidad (West Indies).  
Tel/Fax: 1 868 662 4030  
E-mail: uwi.hariharan@gmail.com

The peak age appears to vary with different geographical locations: while the average age is 53 years old in the Western countries, it is 33 years old in India.<sup>2</sup> This condition is also associated with pregnancy,<sup>3</sup> Meckel's diverticulum,<sup>4</sup> previous abdominal surgery,<sup>5</sup> colonoscopy<sup>6</sup> and laparoscopic appendectomy.<sup>7</sup>

A rare occurrence of volvulus of an appendiceal mucocele has been documented.<sup>8</sup> Appendiceal mucocele can cause intestinal obstruction,<sup>9-11</sup> pseudomyxoma peritonei<sup>12</sup> and intussusception.<sup>13</sup> However, there is no record of a cecal volvulus associated with an appendiceal mucocele. We report a case with such association.

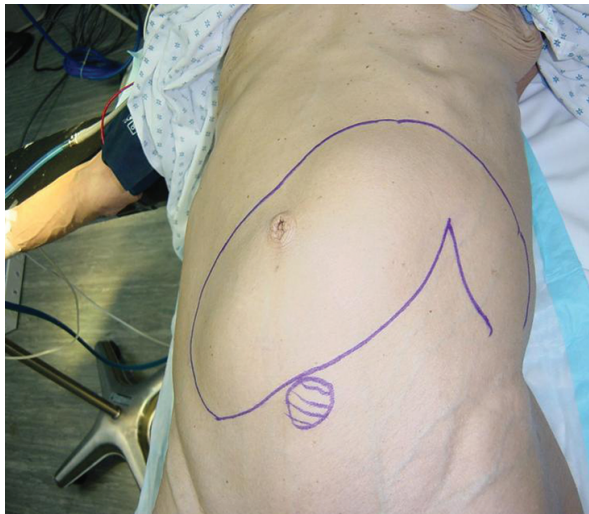### Case report

An otherwise healthy 75-year-old woman presented with a 1-day history of abdominal distension, constipation, generalized colicky pain and vomiting. On examination, she was an elderly asthenic female, afebrile and in no obvious distress. There was asymmetric tympanic distension of the abdomen (Figure 1). A tense smooth mass was felt across the mid-abdomen with a hard 6 cm nodular area inferiorly. Plain radiograph showed a grossly distended bowel loop with an opacity inferiorly, corresponding to the hard mass (Figure 2). Since this finding is classical for cecal volvulus and no other bowel part was distended, no computerized tomographic (CT) imaging was done because a firm diagnosis of cecal volvulus was made and urgent surgery undertaken. Under general anaesthesia, a laparotomy revealed the following findings: distended caecum with the right colon twisted clockwise to the right, and mucocele of the appendix, densely adherent to the caecum and ascending colon, giving an appearance of a C-shaped mass (Figure 3).

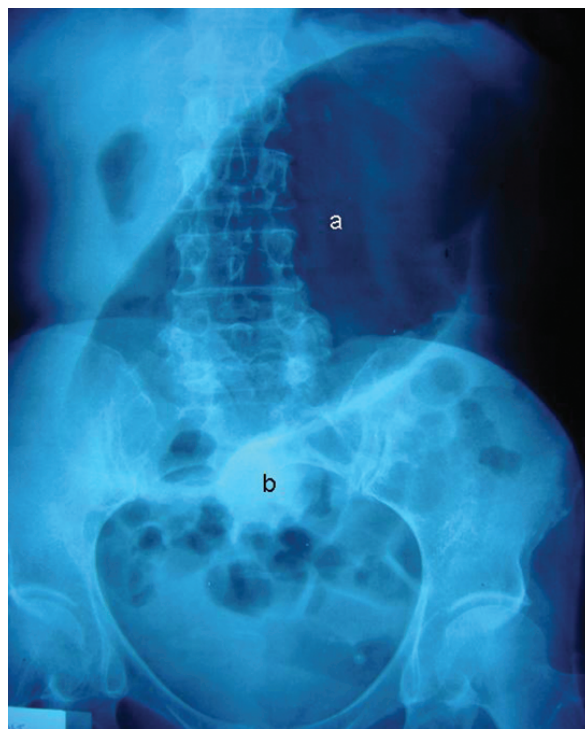
The volvulus was untwisted and a right hemico-

lectomy with an end-to-end ileo-transverse colonic anastomosis was done. Gross anatomical pathology showed an obstruction of the right colon and histology demonstrated a benign mucocele of the appendix. The patient recovered uneventfully, tolerated oral fluids 48 hours after surgery and was discharged home on day 5. Currently, 8 years after surgery, she is well and asymptomatic.

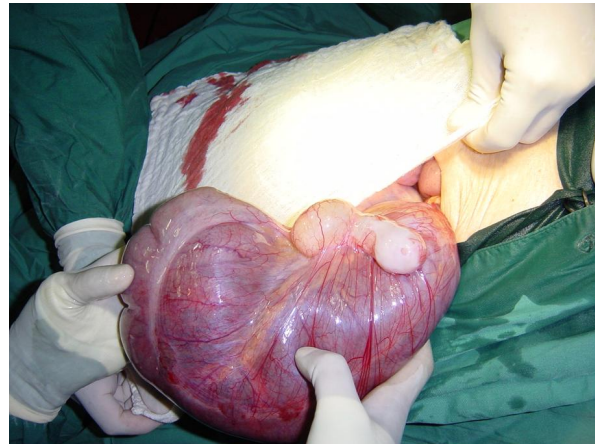
**Figure 1.** Asymmetric distension of the abdomen.



**Figure 2.** Plain radiograph of the abdomen.



**Figure 3.** Intraoperative findings.



### Discussion

Volvulus of the cecum is associated with abnormal laxity of the right mesocolon and most commonly presents in the 20- to 35-year-old age groups.<sup>1</sup> Our patient was a 75-year-old elderly and must have been born with abnormally lax mesentery of the right colon, but a precipitating event was needed to cause her cecum to twist. The only abnormality found during surgery was the mucocele of the appendix, which may have contributed by its bulk while the adhesions to the cecum and the ascending colon could have increased its mass as a unit facilitating the volvulus.

The condition is uncommon in children though a few cases have been reported.<sup>14,15</sup> Although cecostomy and untwisting with cecopexy have been described as more conservative management options, resection and anastomosis is regarded as the treatment of choice.<sup>16</sup>

CT imaging may have a role in diagnosing this condition, especially when there is a doubt in the clinical and plain radiographic diagnosis. Studies have shown that the plain radiograph was highly sensitive for the presence of a disproportionately dilated bowel loop and a pattern of distal small bowel occlusion (91%), followed by a single air-fluid level in the cecum and collapse of the distal colon (82%).<sup>17</sup> With respect to CT, the classical signs were the "coffee bean" sign, with a single air-fluid level and collapse of the left colon, and the "whirl sign". The sensitivity was 100% and 86%, respectively.<sup>17</sup> The 'whirl sign' is not pathognomonic of cecal volvulus and it can be present in the volvulus of small gut and sigmoid colon.<sup>18</sup> In our situation, a firm

diagnosis was made by the plain radiograph and the abdominal distension required an urgent surgery. Similarly, although laparoscopic cecopexy has been described for the condition, only a few cases have been treated<sup>19</sup> and we do not have experience with this procedure.

Atypical presentations of cecal volvulus include other metachronous volvulus of the gastrointestinal tract,<sup>20</sup> combined ileocecal and sigmoid volvulus<sup>21</sup> as a complication of laparoscopy<sup>22</sup> or colonoscopy,<sup>23</sup> association with multiple pregnancy,<sup>24</sup> antegrade colonic enema,<sup>25</sup> and associated mesenteric dermoid.<sup>26</sup> In our patient, there was no malignancy associated with the cecal volvulus, and the benign appendiceal mucocele was the only additional finding. To our knowledge, this association has not been reported in the literature.

In summary, cecal volvulus should be suspected in patients of all age groups presenting with an asymmetric right sided distension of the abdomen.

## References

- Bitterman RA, Peterson MA. Volvulus. In: Marx JA, Hockberger RS, Walls RM, eds. Rosen's emergency medicine: concepts and clinical practice. 5th ed. St. Louis, MO: Mosby, 2002:1335.
- Rabinovici R, Simansky DA, Kaplan O, Mavor E, Manny J. Cecal volvulus. *Dis Colon Rectum* 1990;33:765-769.
- Montes H, Wolf J. Cecal volvulus in pregnancy. *Am J Gastroenterol* 1999;94:2554-2556.
- Neidlinger NA, Madan AK, Wright MJ. Meckel's diverticulum causing cecal volvulus. *Am Surg* 2001;67:41-43.
- Tejler G, Jiborn H. Volvulus of the cecum. Report of 26 cases and review of the literature. *Dis Colon Rectum* 1988; 31:445-449.
- Viney R, Fordan SV, Fisher WE, Ergun G. Cecal volvulus after colonoscopy. *Am J Gastroenterol* 2002;97:3211-3212.
- McIntosh SA, Ravichandran D, Wilkink AB, Baker A, Purushotham AD. Cecal volvulus occurring after laparoscopic appendectomy. *JSL* 2001;5:317-318.
- Rudloff U, Malhotra S. Volvulus of an appendiceal mucocele: report of a case. *Surg Today* 2007;37:514-517.
- Spiridakis K, Kreanka M, Kokkinos I, Panagiotakis G, Kokkinakis T, Kandylakis S. Intestinal obstruction secondary to appendiceal mucocele: case report and review of literature. *G Chir* 2007;28:274-276.
- Akers DL, Hendrickson MF, Markowitz IP, Kerstein MD. Volvulus of an appendiceal mucocele presenting as a small bowel obstruction. *J La State Med Soc* 1988;140:29-33.
- Mourad FH, Hussein M, Bahlawan M, Haddad M, Tawil A. Intestinal obstruction secondary to appendiceal mucocele. *Dig Dis Sci* 1999;44:1594-1599.
- Landen S, Bertrand C, Maddern GJ, Herman D, Pourbaix A, de Neve A, Schmitz A. Appendiceal mucoceles and pseudomyxoma peritonei. *Surg Gynecol Obstet* 1992;175:401-404.
- Tsunoda T, Eto T, Maeda H, Mochinaga N, Terada M, Matsuo S, Tsuchiya R, Takahara Y. Intussusception of an appendiceal mucocele: report of a case. *Surg Today* 1992; 22:470-473.
- Mansoor K, Al Hamidi S, Khan AM, Samujh R. Rare case of pediatric cecal volvulus. *J Indian Assoc Pediatr Surg* 2009;14:110-112.
- Housni B, Khatouf M, Chater L, Bouabdellah Y, Elomari N, Harandou M, Kanjaa N. Cecal volvulus: a case report in a child. *Arch Pediatr* 2005;12:1241-1243.
- Madiba TE, Thomson SR. The management of cecal volvulus. *Dis Colon Rectum* 2002;45:264-267.
- López Pérez E, Martínez Pérez MJ, Ripollés González T, Vila Miralles R, Flors Blasco L. Cecal volvulus: imaging features. *Radiologia* 2010;52:333-341.
- Suárez Vega VM, Martí de Gracia M, Verón Sánchez A, Alonso Gamarra E, Garzón Moll G. Trapped on the "whirl": diagnostic sign on emergency CT. *Emerg Radiol* 2010;17:139-147.
- Baldarelli M, De Sanctis A, Sarnari J, Nisi M, Rimini M, Guerrieri M. Laparoscopic cecopexy for cecal volvulus after laparoscopy. Case report and a review of the literature. *Minerva Chir* 2007;62:201-204.
- Averginos DV, Llaguna OH, Friedman RL. A unique case of recurrent metachronous volvulus of the gastrointestinal tract. *Arch Surg* 2009;144:1176-1178.
- El Bouhaddouti H, Lamrani J, Louchi A, El Yousfi M, Aqodad N, Benajah D, El Abkari M, Ibrahim A. Combined ileocecal and sigmoid colonic volvulus. *J Chir (Paris)* 2009;146:495-496.
- Pernin M, Legname M, Naulet P, Bertinotti C, Delpy R, Rey P. Cecal volvulus: an exceptional complication of colonoscopy. *Gastroenterol Clin Biol* 2009;33:1013-1016.
- Agahi A, Harle R. A serious but rare complication of laparoscopic adjustable gastric banding: bowel obstruction due to caecal volvulus. *Obes Surg* 2009;19:1197-1200.
- Chase DM, Sparks DA, Dawood MY, Perry E. Cecal volvulus in a multiple-gestation pregnancy. *Obstet Gynecol* 2009;114:475-477.
- Kokoska ER, Herndon CD, Carney DE, Lerner M, Grosfeld JL, Rink RC, West KW. Cecal volvulus: a report of two cases occurring after the antegrade colonic enema procedure. *J Pediatr Surg* 2004;39:916-919.
- Torreggiani WC, Brenner C, Micallef M, O'Laoide R. Case report: caecal volvulus in association with a mesenteric dermoid. *Clin Radiol* 2001;56:430-432.