



Contents lists available at ScienceDirect

International Journal of Surgery Case Reports

journal homepage: www.casereports.comCervical leverage: A new procedure to deliver deep retrosternal goitres without thoracotomy[☆]

Vijay Naraynsingh, Ian Ramarine, Shamir O. Cawich*, Ravi Maharaj, Dilip Dan

Department of Clinical Surgical Sciences, University of the West Indies, St. Augustine Campus, Trinidad and Tobago

ARTICLE INFO

Article history:

Received 19 July 2013

Received in revised form 7 August 2013

Accepted 26 August 2013

Available online 12 September 2013

Keywords:

Goitre

Thyroid

Thoracotomy

Retrosternal

Mediastinal

ABSTRACT

INTRODUCTION: Although most retrosternal goitres can be removed through a standard collar incision, some cases require extra-cervical incisions for complete resection. We report a new technique to remove large retrosternal goitres without extra-cervical incisions.

PRESENTATION OF CASE: We present two cases in which a US Army-Navy (Parker-Langenback) retractor was used to deliver large retrosternal components into the cervical incisions.

DISCUSSION: This technique is useful in cases where the retrosternal component extends beyond the reach of the exploring finger and a well-developed plane can be developed between the gland and surrounding tissue.

CONCLUSION: The cervical leverage technique allows removal of a large retrosternal component through a cervical incision, thereby avoiding the attendant morbidity of a thoracotomy or median sternotomy. It should not be used if there is suspected neoplastic disease, dense adherence to or invasion of surrounding intra-thoracic structures.

© 2013 The Authors. Published by Elsevier Ltd on behalf of Surgical Associates Ltd. All rights reserved.

1. Introduction

Between 2%¹ and 20%² of thyroidectomies are performed for retrosternal goitres. Although most can be successfully removed through a standard collar incision, some cases require a median sternotomy or even a lateral thoracotomy for complete resection.^{1–5} In 2006, Marzouk⁶ described the technique of using a small mediastinotomy in the second intercostal space to assist in mobilizing the inferior pole, by pushing it upwards to facilitate delivery into the neck wound. This technique avoids a sternotomy or thoracotomy and the attendant complications. We report two cases in which an alternative technique was used to deliver the retrosternal component through the cervical incision without a thoracic incision, thus further minimizing morbidity, decreasing operating time and hospital stay.

2. Presentation of cases

2.1. Case 1

A 48-year old obese (BMI 38) man presented with intermittent chest discomfort when lying flat. Computer tomography (CT)

[☆] This is an open-access article distributed under the terms of the Creative Commons Attribution-NonCommercial-No Derivative Works License, which permits non-commercial use, distribution, and reproduction in any medium, provided the original author and source are credited.

* Corresponding author. Tel.: +1 878 315 7414; fax: +1 876 620 4560.

E-mail addresses: socawich@hotmail.com, socawich@allpsgroup.com (S.O. Cawich).

scans revealed a superior mediastinal mass in continuity with the left lobe of the thyroid that extended just below the aortic arch and displaced the intra thoracic trachea to the right (Fig. 1). He had a short thick neck and no palpable thyroid mass in the neck. Thyroid function tests were normal. A decision was made to proceed with left thyroid lobectomy and removal of the intra-thoracic portion with preparation for a median sternotomy, if needed.

A collar incision was made and the strap muscles were separated in the midline down to the suprasternal notch. The left lobe was completely mobilized by division of the middle thyroid vein and ligation of the inferior and superior thyroid vessels and division of the isthmus. This permitted delivery of the cervical portion but there was a narrow “waist” at the thoracic inlet beyond which the goitre expanded into the superior mediastinum. Traction and digital mobilization attempts resulted in severing of the left lobe from the thoracic component at the “waist” of the multinodular goitre.

The thoracic portion was then mobilized by digital dissection staying immediately on the capsule to develop a well-defined plane. However, it extended just beyond the reach of the exploring finger and it was not possible to reach the inferior most border of the goitre. In order to assist in delivery of this goitre, a US Army-Navy (Parker-Langenback) retractor was guided by the left index finger and placed against the inferior pole of the mass (Fig. 2). Application of traction on the retractor allowed us to gain leverage on the mass in order to allow continued development of the plane with the index finger (Fig. 3). This facilitated delivery of the gland into the neck wound (Figs. 4 and 5). Although the gland was delivered in its entirety, traction on the retractor produced a tear in one of the colloid nodules (Fig. 6).

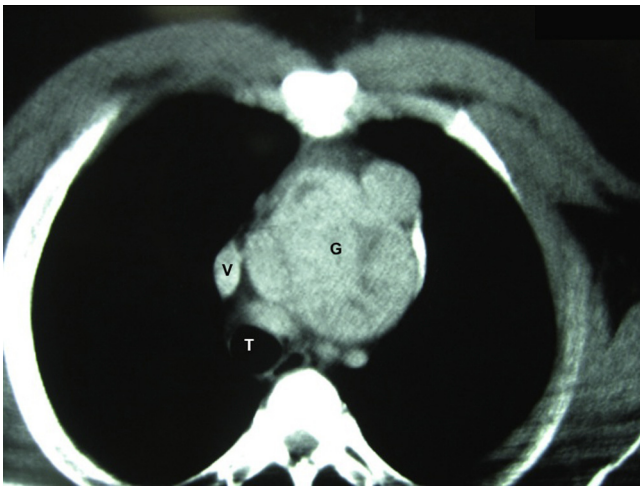


Fig. 1. CT of the thorax showing a large goitre in the superior mediastinum (G) displacing the intra-thoracic trachea (T) and vena cava (V) to the right.

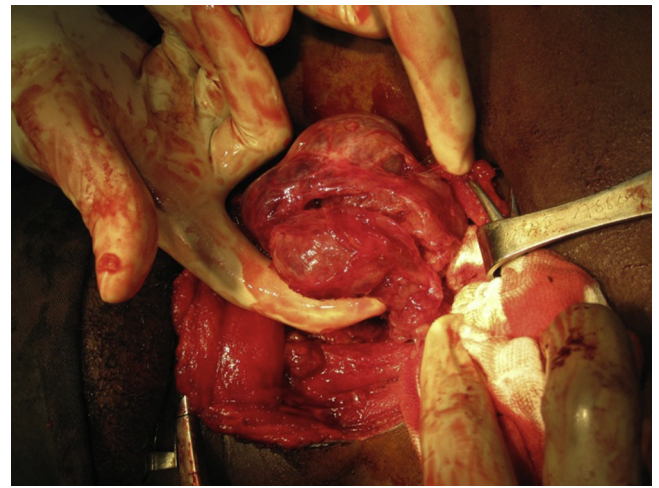


Fig. 4. Cervical leverage facilitates delivery of the goitre into the neck wound.

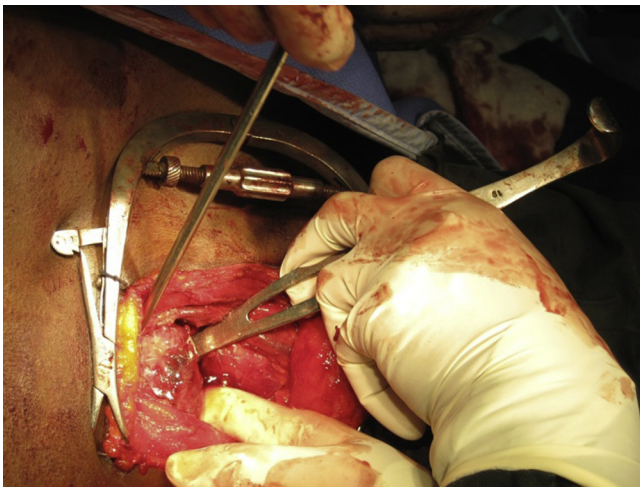


Fig. 2. A Parker-Langenback (US Army-Navy) retractor is guided by the left index finger and placed against the inferior pole of the goitre.

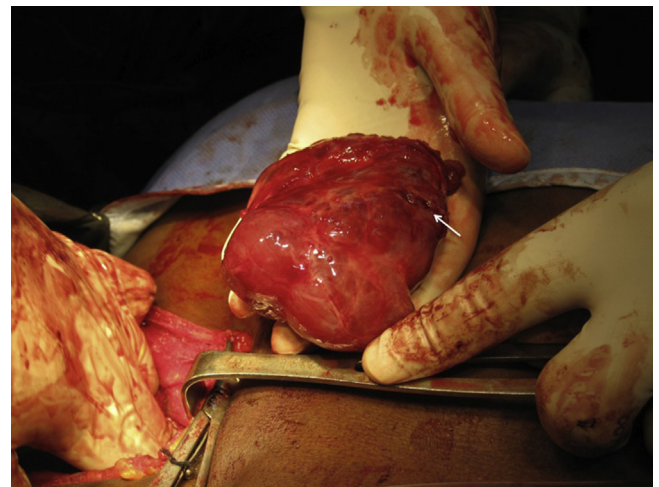


Fig. 5. Complete delivery of the goitre through the cervical incision. White arrow marks a capsular tear in one of the colloid nodules from traction on the Parker-Langenback (US Army-Navy) retractor.

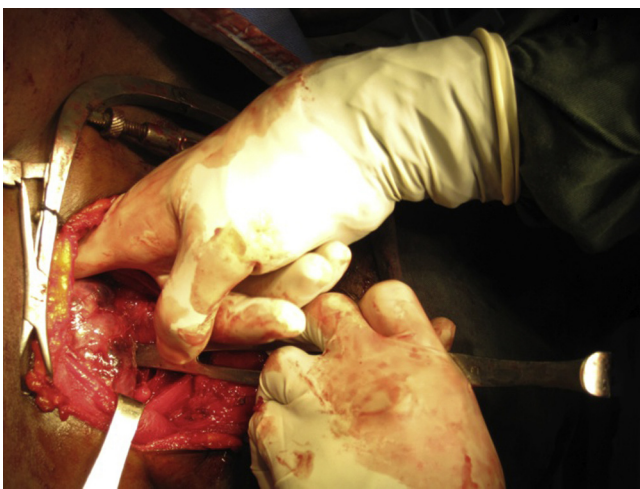

Fig. 3. Traction applied with the Parker-Langenback (US Army-Navy) retractor allows leverage on the goitre in order to allow continued development of the plane with the index finger.

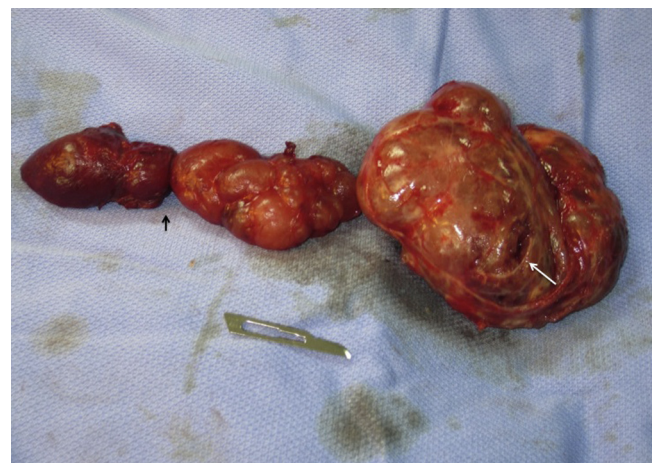

Fig. 6. Extracted specimen showing the narrow "waist" (black arrow) and the large intra-thoracic portion of the goitre. The capsular tear in a colloid nodule is marked by the white arrow.

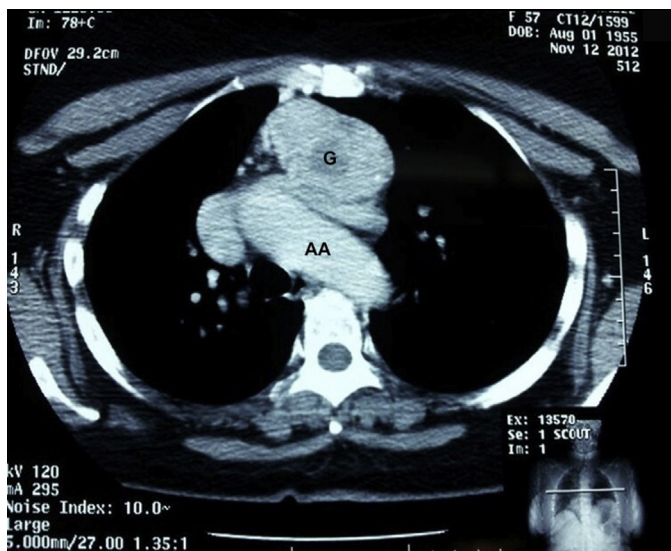


Fig. 7. CT Scan of the thorax showing the intra-thoracic goitre (G) extending into the superior mediastinum beyond the aortic arch (A).

The cavity in the superior mediastinum was packed for five minutes with a laparotomy swab in an attempt to arrest mild venous oozing. Haemostasis was achieved assisted by the use of a headlight and electrocautery. The wound was packed with a gelfoam® sponge (Pharmacia and Upjohn Company, Michigan, USA) and the wound closed in layers without drains. He recovered well with a normal voice and was discharged 48 h postoperatively.

2.2. Case 2

A 64-year old man presented with discomfort in the neck on swallowing. He had moderate enlargement of the left lobe of thyroid with tracheal deviation to the right. Thyroid function tests were normal but CT scan showed the left thyroid lobe extending into the superior mediastinum, beyond the tracheal bifurcation and aortic arch (Fig. 7).

At surgery via a collar incision, the left lobe of thyroid was found to be grossly multinodular and extended in continuity with the mediastinal mass. The cervical portion was completely mobilized, delivered into the wound and used for traction while digitally developing a well-defined plane between the goitre and the superior mediastinal tissue. However, the goitre extended just beyond the reach of the finger. A US Army-Navy (Parker-Langenback) retractor, guided by the left index finger, was slid to the lower border of the goitre (Fig. 8). This was used to achieve leverage on the goitre allowing digital dissection of the small remaining adherent portion (Fig. 9). The goitre was delivered through the neck incision with very little bleeding (Figs. 10 and 11). The wound was closed without drains. He recovered uneventfully and was discharged 48 h postoperatively.

3. Discussion

It is well recognized that adding a median sternotomy or lateral thoractomy to a collar incision for removal of a retrosternal goitre increases post operative pain, morbidity and hospital stay.^{1–5} Fortunately, most retrosternal goitres can be safely delivered through a neck incision^{7–9} with an extra-cervical incision becoming necessary in 2%¹ to 30%⁵ of cases.

Traction on the goitre from above using either a suture, tissue forceps or manual traction can result in separation of the cervical part from the thoracic portion as the colloid tissue may be

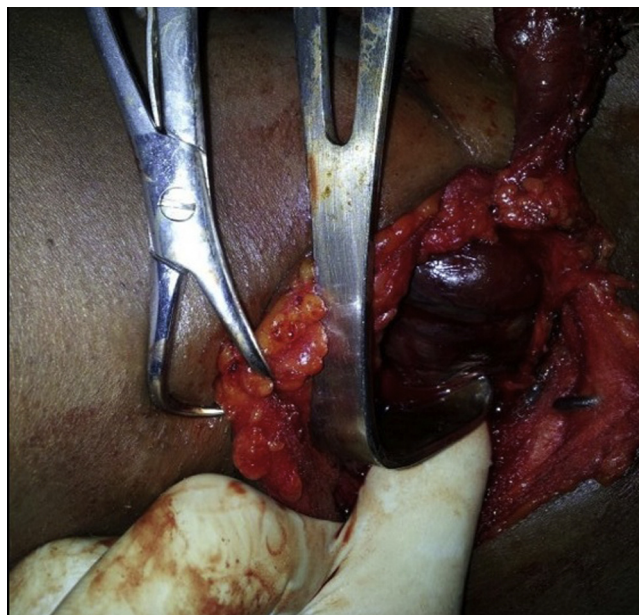


Fig. 8. A Parker-Langenback (US Army-Navy) retractor is guided by the left index finger to the lower border of the goitre.

friable and the “bridge” of tissue between these two portions might be narrow, as in our first case. Marzouk⁶ described the use of a small transverse incision at the second intercostal space to digitally mobilize the mediastinal component beyond the reach of the exploring suprasternal finger. By mobilizing and pushing the mediastinal component upward into the neck wound, they avoided a median sternotomy.⁶

The cervical leverage technique described here takes this one step forward by omitting the thoracic incision. Pulling the goitre upwards with the right angle of a US Army-Navy (Parker-Langenback) retractor gives the small additional leverage needed

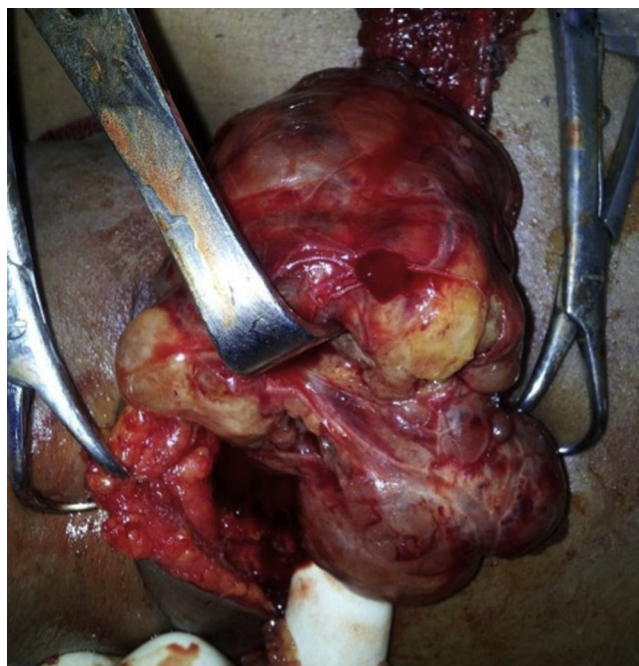


Fig. 9. The Parker-Langenback (US Army-Navy) retractor is used to achieve leverage on the goitre allowing digital dissection of the adherent intra-thoracic portion.

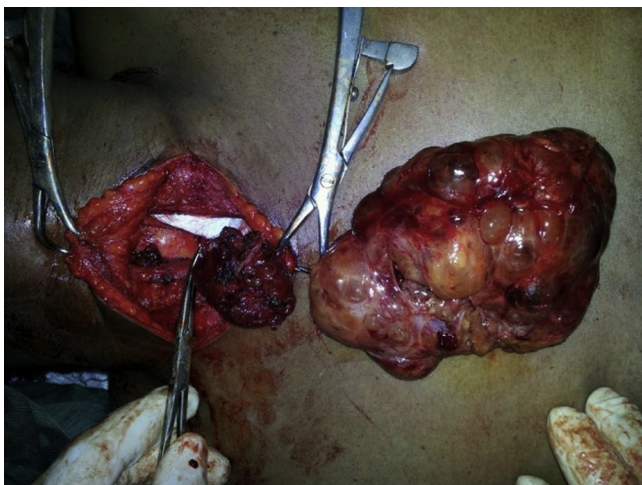

Fig. 10. The intra-thoracic component is completely delivered into the neck wound.

for the exploring finger to reach the inferior most part of the goitre and deliver it into the neck wound.

There is potential danger in the technique if the plane between the goitre and the surrounding mediastinal tissue is not clearly defined. For this reason, we invest time to carefully create a well-developed extra-capsular plane by digital mobilization and the retractor is always guided to the lowest portion of the gland by the index finger. There is also a risk of capsular rupture at the sub-sternal component since the colloid tissue is friable and the retractor is rigid, as happened in our first case. However, a small amount of spillage is irrelevant in benign nodular disease and the resulting haemorrhage from the goitre is negligible since the thyroid would have been devascularized by ligation of the vascular pedicles during mobilization of the cervical portion. While we recommend its use on benign multinodular disease (which accounts for the majority of retrosternal goitres) we would not utilize it in suspected malignancy because of possible adhesions to surrounding major vessels and likely tumour spillage if the rigid retractor tears the thyroid mass.

Haemorrhage from the mediastinum is a theoretic concern with this technique. However, we have not found this to be problematic because the bleeding is usually venous in origin and can be arrested relatively easily by packing and compression. In most cases, there is no arterial supply to the intra-thoracic component arising from

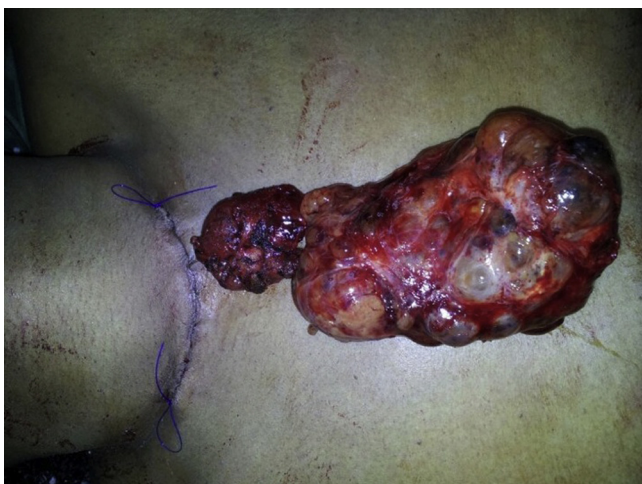

Fig. 11. Goitre placed on the chest wall after excision to demonstrate the size of the intra-thoracic component.

the mediastinum.¹⁰ The most commonly encountered arterial supply within the thorax is the arteria thyroidea ima that is present in 3–10% of persons.¹⁰ While the arteria thyroidea ima has a variable origin, it consistently travels on the anterior surface of the trachea to enter and supply the isthmus from below. The isthmus, however, is fixed to the second, third and fourth tracheal rings and does not descend into the mediastinum. Therefore, when present, the arteria thyroidea ima is also accessible in the neck. Otherwise, the gland receives arterial supply from the superior and inferior thyroid arteries that originate from the external carotid and thyrocervical trunk respectively. As both pairs of arteries originate within the neck, they can usually be identified and controlled during the cervical dissection.

The distinction should be made between a retrosternal goitre in which the cervical and mediastinal components are connected^{5,11} and a primary intra-thoracic goitre¹² or aberrant goitre^{13–15} in which the mediastinal component is separate. The aberrant goitre is reported to have an abnormal arterial supply from the thorax in up to 14% of cases.⁵ For this reason, the technique should probably not be used in the presence of aberrant goitres. To exclude the presence of aberrant goitres, we routinely investigate our patients with CT scans and we also ensure that a properly timed arterial and venous phase is completed to detect the rare instances where aberrant vascular anatomy may be encountered.^{10,16,17}

4. Conclusion

We believe that the US Army-Navy (Parker-Langenback) retractor can be safely used in selected cases where a sub-sternal goitre extends beyond the reach of the exploring finger and a well-developed plane can be developed between the gland and surrounding tissue. It should not be used if there is suspected neoplastic disease, dense adherence to or invasion of surrounding intra-thoracic structures.

Conflict of interest

There are no potential sources of conflict declared by any of the authors.

Funding

None.

Ethical approval

Written informed consent was obtained from the patients for publication of this case series and accompanying images. A copy of the written consent is available for review by the Editor-in-Chief of this journal on request.

Author contributions

VN participated in data collection, study design, writing and analysis. IR participated in data collection and analysis. SOC participated in study design, writing and analysis. RM participated in writing and analysis.

References

1. White ML, Doherty GM, Gauger PG. Evidence-based surgical management of substernal goiter. *World J Surg* 2008;**32**(7):1285–300.
2. Agha A, Glockzin G, Ghali N, Iesalnieks I, Schlitt HJ. Surgical treatment of substernal goiter: an analysis of 59 patients. *Surg Today* 2008;**38**:505–11.
3. Kilic D, Findikcioglu A, Ekici Y, Alemdaroglu U, Hekimoglu K, Hatipoglu A. When is transthoracic approach indicated in retrosternal goiters? *Ann Thorac Cardiovasc Surg* 2011;**17**(3):250–3.

4. Machado NO, Grant CS, Sharma AK, al Sabti HA, Kolidyan SV. Large posterior mediastinal retrosternal goiter managed by a transcervical and lateral thoracotomy approach. *Gen Thorac Cardiovasc Surg* 2011;**59**(7):507–11.
5. Cichon S, Anielski R, Konturek A, Baczynski M, cichori W, Orkicki P. Surgical management of mediastinal goiter: risk factors for sternotomy. *Langenbecks Arch Surg* 2008;**393**(5):751–7.
6. Rathinam S, Davies B, Khalil-Marzouk JF. Marzouk's procedure: a novel combined cervical and anterior mediastinotomy technique to avoid median sternotomy for difficult retrosternal thyroidectomy. *Ann Thorac Surg* 2006;**82**(2):759–60.
7. Ahmed ME, Ahmed EO, Mahadi SI. Retrosternal goiter: the need for median sternotomy. *World J Surg* 2006;**30**(11):1945–9.
8. Picardi N, Di Rienzo M, Annunziata A, Bartolacci M, Relmi F. Transclavicular approach for delivery of intrathoracic giant goiter. An alternative surgical option. *Ann Ital Chir* 1999;**70**(5):741–8.
9. Torre G, Borgonovo G, Amato A, Arezzo A, Ansaldo G, De Negri A, et al. Surgical management of substernal goiter: analysis of 237 patients. *Am Surg* 1995;**61**(9):826–31.
10. Toni R, Della Casa C, Mosca S, Malaguti A, Castorina S, Roti E. Anthropological variations in the anatomy of the human thyroid arteries. *Thyroid* 2003;**13**(2):183–92.
11. Houck WV, Kaplan AJ, Reed CE, Cole DJ. Intrathoracic aberrant thyroid: identification critical for appropriate operative approach. *Am Surg* 1998;**64**(4):360–2.
12. Foroulis CN, Rammos KS, Sileli MN, Papakonstantinou C. Primary intrathoracic goiter: a rare and potentially serious entity. *Thyroid* 2009;**19**(3):213–8.
13. Hall TS, Caslowitz P, Popper C, Smith GW. Substernal goiter versus intrathoracic aberrant thyroid: a critical difference. *Ann Thorac Surg* 1988;**46**(6):684–5.
14. Neri S, Chen F, Fujinaga T, Sato K, Sonobe M, Shoji T, et al. Mediastinal aberrant goiter; report of a case. *Kyobu Geka* 2007;**60**(12):1118–21.
15. Gamblin TC, Jennings GR, Christie DB, Thompson WM, Dalton ML. Ectopic thyroid. *Ann Thorac Surg* 2003;**75**(6):1952–3.
16. Slaba S, Abi-Khalil S, Hachem K, Nassar-Slaba J. Aberrant thyroidoververtebral artery. *J Mal Vasc* 2007;**32**(2):112–5.
17. Yilmaz E, Celik HH, Durgun B, Atasever A, Ilgi S. Arteria thyroidea ima arising from the brachiocephalic trunk with bilateral absence of inferior thyroid arteries: a case report. *Surg Radiol Anat* 1993;**15**(3):197–9.

Open Access

This article is published Open Access at sciedirect.com. It is distributed under the [IJSCR Supplemental terms and conditions](#), which permits unrestricted non commercial use, distribution, and reproduction in any medium, provided the original authors and source are credited.