

## INNOVATION IN SURGERY

# Technical note: rapid, large-volume resuscitation at resuscitative thoracotomy by intra-cardiac catheterization

Shamir O Cawich<sup>†\*</sup> and Vijay Naraynsingh<sup>†</sup>

Department of Clinical Surgical Sciences, University of the West Indies, St Augustine Campus, Trinidad &amp; Tobago

\*Correspondence address. Department of Clinical Surgical Sciences, University of the West Indies, St Augustine Campus, Trinidad & Tobago. Fax: 1-868-622-9909; Tel: 1-868-798-9627; E-mail: socawich@hotmail.com

## Abstract

An emergency thoracotomy may be life-saving by achieving four goals: (i) releasing cardiac tamponade, (ii) controlling haemorrhage, (iii) allowing access for internal cardiac massage and (iv) clamping the descending aorta to isolate circulation to the upper torso in damage control surgery. We theorize that a new goal should be achieving rapid, large-volume fluid resuscitation and we describe a technique to achieve this.

## INTRODUCTION

With penetrating trauma reaching epidemic proportions in the Caribbean [1], emergency room (ER) thoracotomies are performed regularly [2]. It may be life-saving by achieving four goals: (i) releasing cardiac tamponade, (ii) controlling haemorrhage, (iii) allowing access for internal cardiac massage and (iv) clamping the descending aorta to isolate circulation to the upper torso in damage control surgery [3, 4]. We theorize that a new goal should be achieving rapid, large-volume fluid resuscitation and we describe a technique to achieve this.

## TECHNIQUE

An important step during ER thoracotomy is to detect cardiac tamponade by opening the pericardium with a vertical incision that avoids the phrenic nerve. The heart is now exposed, providing the perfect opportunity for catheterization.

In this technique, we place a large, curved Satinsky clamp across the base of the right atrial appendage. Sharp scissors are used to make a 5-mm incision in the atrial appendage. Bleeding is minimal once the Satinsky clamp effectively isolates the appendage. A 20Fr Foley's catheter is then inserted into the incision, ensuring that the balloon is fully within the atrial appendage. The balloon is not inflated because there is insufficient space with the clamp applied. A heavy suture with a round-bodied needle is used to place a purse string around the incision. The suture is tied firmly to achieve a water tight seal around the catheter.

Before releasing the Satinsky clamp, an infusion set is applied to the drainage port of Foley's catheter. A pressure infuser is applied to a bag of warmed isotonic crystalloids—or it can be squeezed by an assistant—providing positive pressure. The clamp is then removed and the balloon inflated to assist in the formation of a seal. The wound is closed easily by tightening the purse-string suture after withdrawing the catheter (Figure 1).

<sup>†</sup>All authors contributed equally to this work

Received: July 27, 2016. Accepted: October 27, 2016

Published by Oxford University Press and JSCR Publishing Ltd. All rights reserved. © The Author 2016.

This is an Open Access article distributed under the terms of the Creative Commons Attribution Non-Commercial License (<http://creativecommons.org/licenses/by-nc/4.0/>), which permits non-commercial re-use, distribution, and reproduction in any medium, provided the original work is properly cited. For commercial re-use, please contact [journals.permissions@oup.com](mailto:journals.permissions@oup.com)

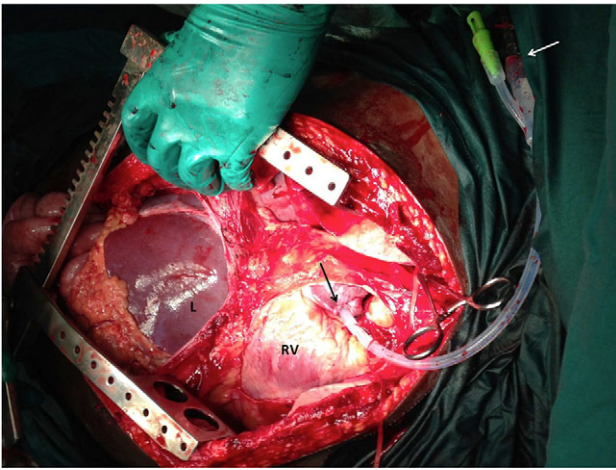


Figure 1: Photograph during an ER thoracotomy. The pericardium has been opened to reveal the right ventricle (RV) and atrium. A Foley's catheter has been introduced into the right atrial appendage (black arrow) and fixated with a purse-string suture. A white arrow demonstrates the fluid administration set connected to Foley's catheter.

## DISCUSSION

Intravenous access is difficult to establish in these volume-depleted patients since there is peripheral vasoconstriction. This technique allows rapid intravenous access because intracardiac catheterization can be achieved in 1–2 minutes with the heart already exposed at ER thoracotomy. Furthermore, the volume of fluid that can be infused exceeds that which can be delivered by peripheral large bore cannulae.

The procedure is easy to perform and requires little specialized equipment. Even in the resource poor setting, a Foley's catheter and suture material are readily available. Application of the Satinsky clamp sequesters blood within the right atrial appendage but it does not interfere with venous return or right atrial outflow tracts. Therefore, there is no interruption of cardiac output while this is performed.

Closure is simple and effective. We have used the technique routinely in our ER thoracotomies with good effect [5]. It allows large-volume fluid infusion to proceed, while the surgeon searches for sources of continued haemorrhage.

## CONCLUSION

Four life-saving goals can be achieved at ER thoracotomy: (i) tamponade release, (ii) haemorrhage control, (iii) internal cardiac massage and (iv) clamping of the descending aorta. Rapid, large-volume resuscitation should be the fifth goal at ER thoracotomy. This technique is easily performed and requires little specialized equipment. It allows better resuscitation that may contribute to increased survival rates.

## ACKNOWLEDGEMENTS

None.

## CONFLICT OF INTEREST STATEMENT

None declared.

## FUNDING

None.

## REFERENCES

1. Ramdass MJ, Cawich SO, Pooran S, Milne D, Ali E, Naraynsingh V. Declaration of a state of emergency in trinidad and tobago: effect on the trauma admissions at the National Referral Trauma Centre. *J Pre-Hosp Disaster Emergency Med* 2015;**30**:1–4.
2. Cawich SO, Mitchell DIG, Williams EW, McFarlane ME, Martin A, Plummer J, et al. Emergency room thoracotomy in Jamaica: a case controlled study. *International Journal of Surgery* 2007;**5**:311–5.
3. Cothren CC, Moore E. Emergency department thoracotomy for the critically injured patient: objectives, indications, and outcomes. *World J Emerg Surg* 2006;**1**:4.
4. Working Group, Ad Hoc Subcommittee on Outcomes, ACS Committee on Trauma. Practice management guidelines for EDT. *J Am Coll Surg* 2001;**193**:303–9.
5. Cawich SO, Mitchell DIG, Crandon IW, Williams EW. Resuscitative thoracotomy for trauma: what is the role in Caribbean countries? *Int J Emerg and Intensive Care Med* 2008;**11**.