

A Cystic Hepatic Lesion: When to Worry?

R Maharaj¹, SV Sakpal², K Deodhar³, A Kulkarni⁴, S Arya⁴, M Ramadwar³, SV Shrikhande¹, V Naraynsingh⁵, PJ Shukla¹

ABSTRACT

A 16-year old female presented to hospital with abdominal pain. Features on computed tomography raised the possibility of biliary cystadenoma or cystadenocarcinoma. She underwent a liver resection, and histopathology confirmed a serous biliary cystadenoma. This case is presented to highlight the radiological features of this uncommon pre-malignant condition as well as to summarize a management algorithm for cystic liver lesions.

Keywords: Biliary cystadenoma, biliary cystadenocarcinoma, multiloculated cyst

La Lesión Cística del Hígado: ¿Cuándo Preocuparse?

R Maharaj¹, SV Sakpal², K Deodhar³, A Kulkarni⁴, S Arya⁴, M Ramadwar³, SV Shrikhande¹, V Naraynsingh⁵, PJ Shukla¹

RESUMEN

Una mujer de 16 años de edad acudió al hospital con un dolor abdominal. Las características observadas con tomografía computarizada apuntaban a un cistoadenoma biliar o un cistoadenocarcinoma como diagnósticos diferenciales. La paciente fue sometida a una resección del hígado, y la histopatología confirmó un cistoadenoma biliar seroso. Presentamos este caso para resaltar los rasgos radiológicos de esta condición premaligna rara, así como para resumir un algoritmo de tratamiento para las lesiones císticas de hígado.

Palabras claves: Cistoadenoma biliar, cistoadenocarcinoma biliar, quiste multiloculado

West Indian Med J 2010; 59 (2): 226

INTRODUCTION

Intrahepatic Biliary Cystadenoma (IBCA) is a rare pre-malignant condition with the highest reported incidence in middle-aged females (1). This case highlights the diagnostic dilemma of a cystic liver lesion at an uncommon age. It is important not to miss the diagnosis of IBCA in view of its malignant potential. In addition, we have discussed the most appropriate modes of treatment for IBCA.

Case Report

A 16-year old female student presented with a three-year history of upper abdominal pain. Ultrasound revealed a cyst with few thin septae in the right lobe of the liver (Fig. 1). Due to persistent pain, a computed tomography (CT) scan of the abdomen and pelvis was performed which also revealed

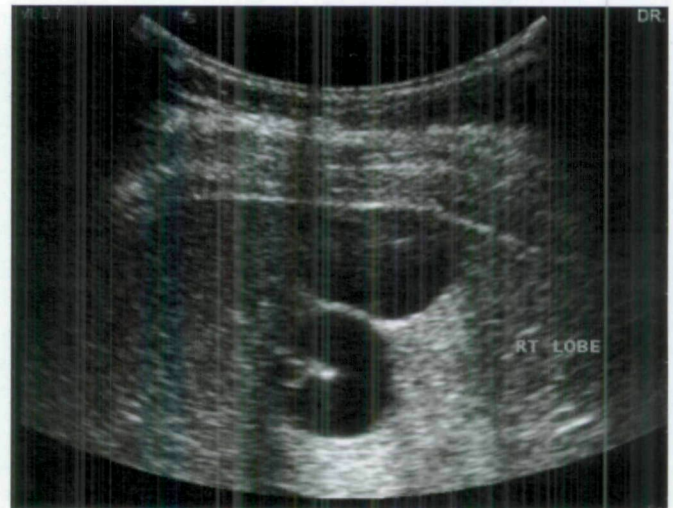


Fig. 1: Ultrasound Scan showing thin walled septated, cystic lesion in the liver. There are no solid components or calcifications.

From: ¹Departments of Gastrointestinal and Hepatopancreatobiliary Surgical Oncology, ⁴Interventional Radiology and ³Pathology, Tata Memorial Hospital, Mumbai, India, ⁵Department of Surgery, The University of the West Indies, Trinidad and Tobago, ²Department of Surgery, Saint Barnabas Medical Centre, Livingston, New Jersey, USA.

Correspondence: Associate Professor PJ Shukla, ¹Departments of Gastrointestinal and Surgical Oncology, Tata Memorial Hospital, Mumbai, India. E-mail: pshukla@doctors.org.uk

a solitary, multiloculated, complex cystic lesion of Couinaud's segments VI and VII (Fig. 2).

The radiological features on both, US and CT, raised the possibility of a biliary cystadenoma or biliary

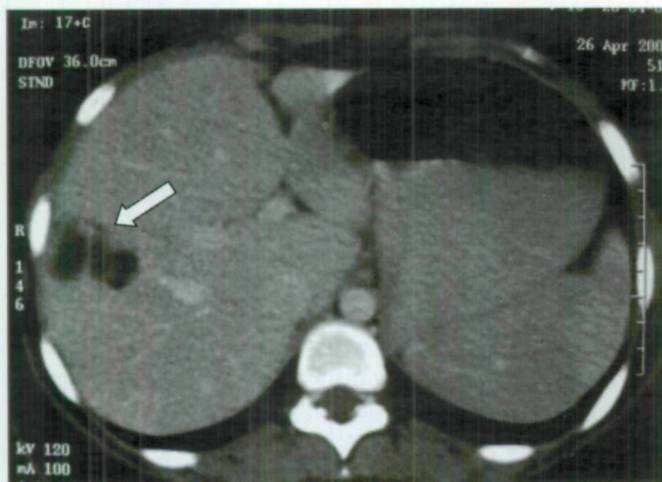


Fig. 2: CT scan showing multiloculated cystic lesion in the right lobe of the liver (arrow). There are no enhancing mural nodules or calcifications seen.

cystadenocarcinoma. In addition, magnetic resonance imaging (MRI) of the liver was also performed to further characterize the cyst (Figs. 3A, 3B). This revealed a few thick

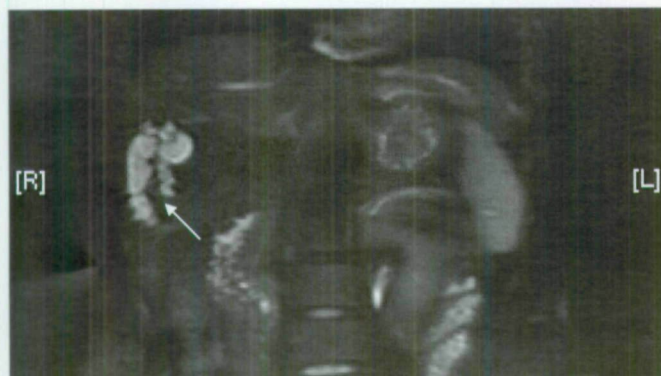

Fig. 3A: Coronal T2W MR image showing a multilocular cyst which appears brightly hyperintense. The thickened septae appear as darkly hypointense bands within the lesion. A nodule is seen along the inferior wall of the lesion (arrow).

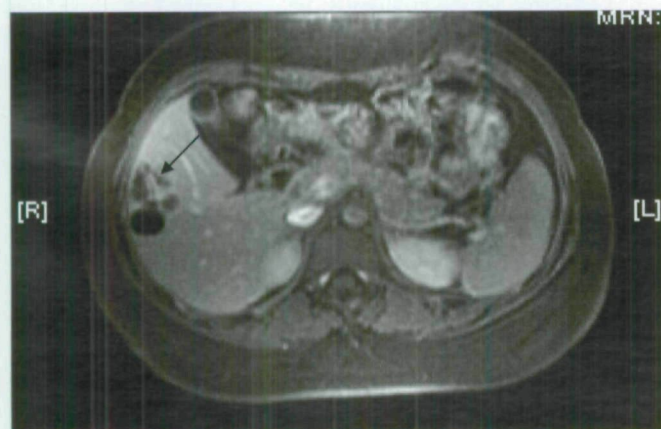


Fig. 3B: T1W post-contrast MR image showing the enhancement of the septae which appear thickened (arrow).

contrast enhancing septae within the cyst and a nodule along its inferior wall, features consistent with the appearance of biliary cystadenoma/carcinoma, thus strengthening the diagnosis. Liver function tests (LFTs), serum α -fetoprotein (AFP) and CA 19-9 were within normal limits. In addition, anti-echinococcal antibodies and viral markers for hepatitis B and C were negative.

In view of the radiological diagnosis, the patient was offered surgical resection. She underwent a non-anatomical resection of the involved segments *via* a bilateral subcostal incision. Frozen section revealed clear, uninvolved margins and the benign nature of the cystic lesion. Final histopathology confirmed a multiloculated, cystic lesion lined by cuboidal and columnar epithelium, which was consistent with a benign serous cystadenoma (Fig. 4). Postoperatively,

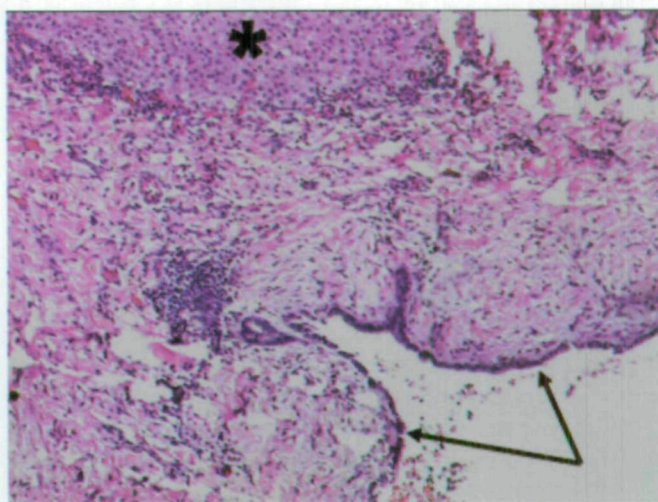


Fig. 4: Photomicrograph of the cut cross-section of the biliary cystadenoma wall (Haematoxylin-eosin stain, 25X) reveals simple cuboidal cell-lined internal wall of the cyst (black solid arrows); fibrous tissue and mild focal inflammation within the cyst wall; and normal adjacent liver cell parenchyma (asterix).

the patient developed a small serous intra-abdominal collection which resolved following percutaneous drainage. At one year follow-up, she remains asymptomatic and a repeat ultrasound was normal.

DISCUSSION

Intrahepatic Biliary Cystadenoma (IBCA) accounts for approximately 5% of all solitary symptomatic cystic liver lesions (2). Two types of biliary cystadenomas are described pathologically mucinous and serous. Mucinous cystadenoma is the predominant type (3). Occurring mainly in middle-aged females, the patients usually present with upper abdominal pain.

The radiological investigations are usually ultrasonography followed by CT or MRI of the liver. The typical US features described are that of a solitary, multiloculated cystic lesion ranging from 1.5–3.5 cm in size (4). On the contrary, a simple hepatic cyst appears uniloculated without internal echoes and very thin barely perceptible walls on US.

On non-enhanced CT study, the simple cyst appears as a homogeneous and hypo-attenuating lesion, with no enhancement of its wall or content after intravenous administration of contrast material. On the other hand, the CT appearance of a biliary cystadenoma is usually a solitary cystic mass with a well-defined thick capsule, and thin internal septae, rarely with capsular calcification. Mural nodules/pedunculated excrescences along the wall are seen more commonly in biliary cystadenocarcinoma than in cystadenoma. Magnetic resonance imaging may help further characterize the cystic lesion (5). The typical features are that of a multi-locular fluid intensity lesion with homogeneous low signal intensity on T1-weighted images and homogeneous high signal intensity on T2-weighted images. Variable fluid levels and signal intensities on both T1- and T2-weighted images, if present, are due to the presence of haemorrhage and proteinaceous fluid or any solid components. Gadolinium-enhanced MRI may show enhancement of the mural nodules and septae. In the present case, MRI showed the septae more clearly with enhancement and also demonstrated a nodule which strengthened the diagnosis of a cystadenoma/cystadenocarcinoma.

The differential diagnoses of a cystic lesion of the liver includes simple cyst, bilioma, haematoma, abscess, echinococcal cyst, cystadenomas, cystadenocarcinoma or even von Meyenburg complex [biliary hamartoma] (6). It follows that the treatment modalities therefore offered could range from aspiration, marsupialization and fenestration, all of which may result in recurrence and malignant change with a poor survival if the lesion was a cystadenoma. Compounding this issue is the fact that the tumour markers, CA 19-9 and AFP, are usually normal and fine needle aspiration cytology is neither sensitive nor specific for IBCA. Though a normal serum CA 19-9 does not rule out a cystadenoma or carcinoma, elevated levels can aid in diagnosis and also in monitoring following complete resection of the lesion (7). In addition, measurement of CA 19-9 in the cystic fluid can be helpful since increased levels can differentiate between neoplastic lesions and benign conditions (8).

This case therefore underlines the importance of the radiological features of IBCA. Pojchamarnwiputh *et al* (9) reviewed the radiologic features of IBCA and found the most common features were a solitary, multi-loculated cyst while Yu *et al* (10) noted the CT scan finding of papillary infolding.

How should one proceed once the diagnosis of IBCA is entertained either clinically or radiologically? Delis *et al* (11) in their paper entitled "IBCA: A Need for Radical Resection" advised the more aggressive approach of formal anatomical hepatectomies while both Thomas *et al* (12) and Colechia *et al* (13) have suggested that enucleation is adequate. A complete (R₀) non-anatomical resection was performed with frozen section histology indicating the benign nature of the lesion as well as free surgical margins. The final histopathology confirmed the diagnosis. This is in keeping with

the approach of Vogt *et al* in their experience of 18 cases (14).

Although malignant hepatic tumours are very rare in the adolescent age group, cystic liver lesions are not uncommon and therefore recognizing a cystadenoma because of its potential to develop into a cystadenocarcinoma is of paramount importance. Simple cysts are quite common and benign in nature. If symptomatic, deroofting of the cyst preferably laparoscopically is recommended (15). On the contrary, this is inadvisable in the case of hydatid cysts since severe anaphylaxis and recurrence may occur due to spillage. Once the diagnosis is confirmed by immunologic testing, these cysts should be treated with percutaneous aspiration, hypertonic saline injection, re-aspiration and drainage (PAIRD) followed by pericystectomy (16).

Imaging therefore does play a central role in the diagnosis of cystic liver lesions and will alert the clinician to features suggesting sinister pathology. We conclude by presenting a treatment algorithm towards the management of symptomatic cystic liver lesions based on imaging findings (Chart 1).

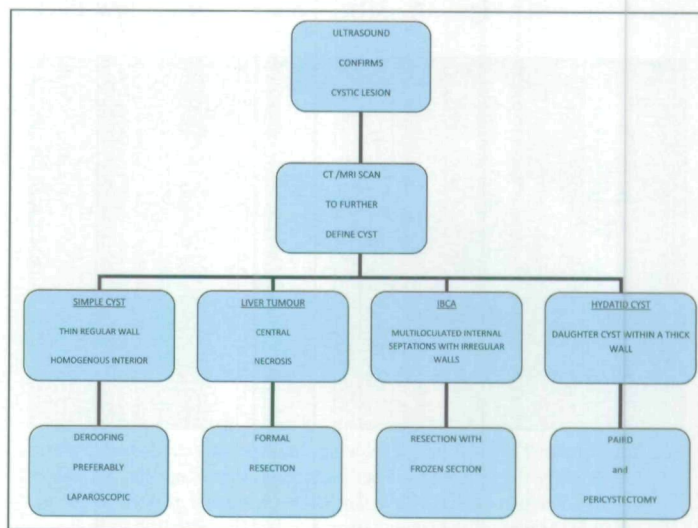


Chart 1. Algorithm for the management of symptomatic cystic liver lesions (based on imaging findings).

REFERENCES

1. Diaz de Liano A, Olivera E, Artieda C, Yarnoz C, Ortiz H. Intrahepatic mucinous biliary cystadenoma. *Clin Transl Oncol* 2007; **9**: 678–80.
2. Del Poggio P. Cystic tumours of the liver: A practical approach. *World J Gastroenterol* 2008; **14**: 3616–20.
3. Colombari R, Tsui WM. Biliary tumors of the liver. *Semin Liver Dis* 1995; **15**: 402–13.
4. Mortelet KJ, Ros PR. Cystic focal liver lesions in the adult: differential CT and MRI imaging features. *Radiographics* 2001; **21**: 895–10.
5. Lewin M, Mourra N, Honigman I, Flejou JF, Park R, Arrive L *et al*. Assessment of MRI and MRCP in the diagnosis of biliary cystadenoma and cystadenocarcinoma. *Eur Radiol* 2006; **16**: 407–13.
6. Karahan OI, Kahrman G, Soyuer I, Ok E. Hepatic von Meyenburg Complex simulating biliary cystadenoma. *Clin Imaging* 2007; **31**: 50–3.
7. Lee JH, Chen DR, Pang SC, Lai YS. Mucinous biliary cystadenoma with mesenchymal stroma: expressions of CA 19-9 and carcino-embryonic antigen in serum and cystic fluid. *Gastroenterol*. 1996; **31**: 732–6.

8. Manouras A, Markogiannakis H, Lagoudianakis E, Katergiannakis V. Biliary cystadenoma with mesenchymal stroma: report of a case and review of the literature. *World J Gastroenterol* 2006; **12**: 6062-9.
9. Pojchamarnwiputh S, Na Chiangmai W, Chotirosniramit A, Lertprasertsuke N. CT of biliary cystadenoma and cystadenocarcinoma. *Singapore Med J* 2008; **49**: 392-6.
10. Yu FC, Chen JH, Yang KC, Wu CC, Chou YY. Hepatobiliary cystadenoma: a report of 2 cases. *J Gastrointestin Liver Dis* 2008; **17**: 203-6.
11. Delis SG, Touloumis Z, Bakoyiannis A, Tassopoulos N, Parakeva K, Athanassiou K et al. IBCA: A Need for Radical Resection. *Eur J Gastroenterol Hepatol* 2008; **20**: 10-4.
12. Thomas KT, Welch D, Trueblood A, Sulur P, Wise P, Gorden DL et al. Effective Treatment of IBCA. *Ann Surg* 2005; **241**: 769-73.
13. Colecchia G, D'Amigo G, Saragani C. Biliary Cystadenoma: 2 reported cases. *Minera Chir* 1997; **52**: 635-8.
14. Vogt DP, Henderson JM, Chmielewski E. Biliary Cystadenoma and Cystadenocarcinoma; A single Centre experience. *J Amer Coll Surg* 2005; **200**: 727-33.
15. Diez J, Decoud J, Gutierrez L, Suhl A, Merello J. Laparoscopic treatment of symptomatic cysts of the liver. *Br J Surg* 1998; **85**: 25-7.
16. Smego RA Jr, Bhatti S, Khaliq AA, Beg MA. Percutaneous aspiration-injection-reaspiration-drainage plus albendazole or mebendazole for hepatic cyst echinococcosis. A met-analysis. *Clin Infect Dis* 2003; **37**: 1073-83.

SUBSCRIPTION FORM
ANNUAL SUBSCRIPTION: J\$8900 (local) US\$150.00 (overseas)



**West
 Indian
 Medical
 Journal**

Name: _____ Title: _____
 Address: _____

 Tel: _____ Fax: _____ e-mail: _____

Please make cheques payable to the West Indian Medical Journal

Card No:

Visa: Mastercard: Keycard: Discover: Debitcard:

Expiry Date: _____

Signature: _____ Date: _____

Thank You - Please return this coupon with your payment to: **West Indian Medical Journal, Faculty of Medical Sciences, The University of the West Indies, Kingston 7, Jamaica, WI.**

E-mail: wimj@uwimona.edu.jm

Website: <http://www.mona.uwi.edu/fms/wimj/>

Tel: (876) 927-1214

Fax: (876) 927-1846

Copyright of West Indian Medical Journal is the property of West Indian Medical Journal (WIMJ) and its content may not be copied or emailed to multiple sites or posted to a listserv without the copyright holder's express written permission. However, users may print, download, or email articles for individual use.